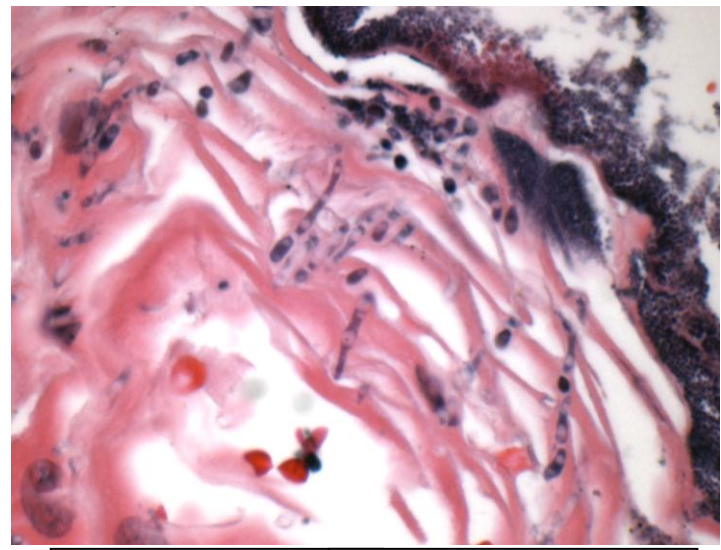
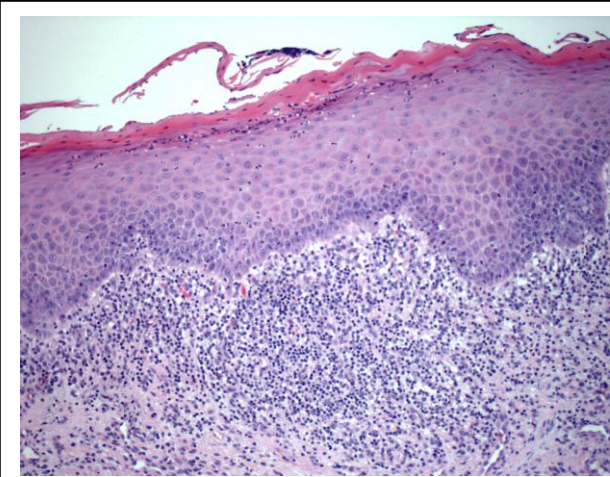
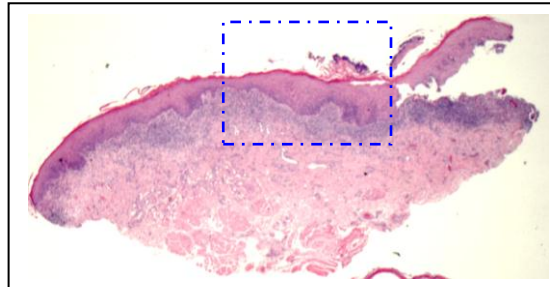


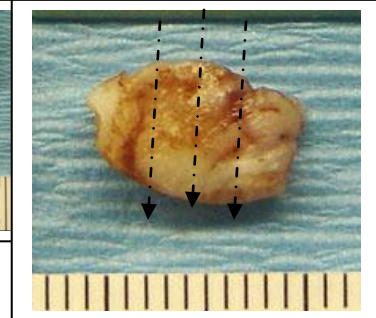
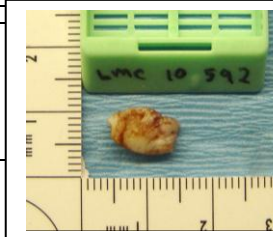
Surgical Pathology Report		
Patients Name	LMC10-	Report Date:
	CPT 88305	ICD-9 - DX code 112.9, 697.0, 528.6
Fax copy to		
Clin Hx:	Ulcerative process of left buccal mucosa, r/ lichen planus	

**Diagnosis: Buccal mucosa, left: Hyperkeratosis, lichenoid mucositis and Candidiasis**

Microscopic examination of the H&E (hematoxylin & eosin) stained slides reveals a lichenoid inflammatory process with Candidiasis. There is no evidence of malignancy. The surface demonstrates variable thickness hyperkeratosis within which there are multifocal areas of septated fungal hyphae and bacterial matte. Maturation of the stratified squamous epithelium is normal with blunted hyperplastic rete. The upper lamina propria contains a diffuse mixed lymphoplasmacytic inflammatory infiltrate. Focal areas of hydropic degeneration are observed and mild exocytosis.



**Gross Exam:** 8/25/10. The specimen is received in formalin labeled with patient's name and consists of ovoid flat mottled soft tissue meas 1.0x.7x.3 cm, quadrisected, 4/1/TE



*Copy*  
 Douglas M. Arendt DDS, MS (electronic)